

# les nouvelles *esthétiques*

AMERICAN

EDITION

LNE—the magazine for skin care and spa professionals

June 2004

\$7.50



# medical dermatology update

## Questions and Answers

### New anti-aging ingredient

**Q:** I have recently heard about the new anti-aging ingredient idebenone. What do you know about it?

**A:** Idebenone is a powerful antioxidant that is soon to be introduced to the anti-aging skin care market. By quenching free radicals, it minimizes the inflammatory reactions that degrade collagen. This new anti-aging cosmetic ingredient should be used together with sunscreen to enhance the prevention of photoaging.

*Fair-complected individuals can show evidence of sun damage as early as their late 20s and early 30s.*

### Stay protected in the sun

**Q:** How much sunscreen should I apply, and how often do I have to apply it to be adequately protected?

**A:** The average adult should apply about two tablespoons of sunscreen per application. Sunscreen should be applied minutes prior to sun exposure and reapplied every two hours. I recommend the use of an SPF 30 or higher sunscreen. Of course, sunscreen is only part of a sun protection strategy, which should include protective clothing, sunglasses and avoidance of midday sun exposure.

### European sunscreens

**Q:** I've heard that there are more effective sun screening ingredients in Europe. Is that true?

**A:** Yes, two UVA sunscreen agents, Mexoryl SL and Tinosorb, are readily available in Europe and Canada. Both of these agents protect more broadly in the UVA light spectrum than Parsol 1789 (avobenzone) and benzophenones, commonly used for UVA protection in

the United States. Both ingredients are in the process of seeking approval in the United States. The latter agent is already available in the United States as an additive in the washer rinse cycle to improve the photoprotection of clothing.

### Glycolics for rough spots

**Q:** I have a client who has rough spots on her decollete and cleavage. She wants me to do something about them. I referred her to a dermatologist. I think they are AKs. Can you tell me what the appropriate method of treatment for these lesions is? Also, is there anything I can do to help diminish their appearance or make them go away? Does glycolic work?



**A:** Actinic keratoses are precancerous lesions. Approximately 20 percent of these lesions ultimately progress to skin cancer. They can be treated by cryotherapy, curettage, topical immunomodulators such as Aldara, topical chemotherapeutic agents such as Effudex and Carac and topical anti-inflammatory agents such as Solareze. Of course, meticulous sun protection is important to lessen further photodamage. Glycolic acid can temporarily smooth the surface of these lesions, but should be avoided in favor of definitive therapy. You were correct to refer your client to a dermatologist for evaluation and treatment.

### Laser for sun damage

**Q:** Years of sun damage start to show up on skin in a person's 30s, right? At that point, what's the best medical option for a woman in her 30s to remove the damage? Is it too early for laser resurfacing?

**A:** Fair-complected individuals who have had significant sun

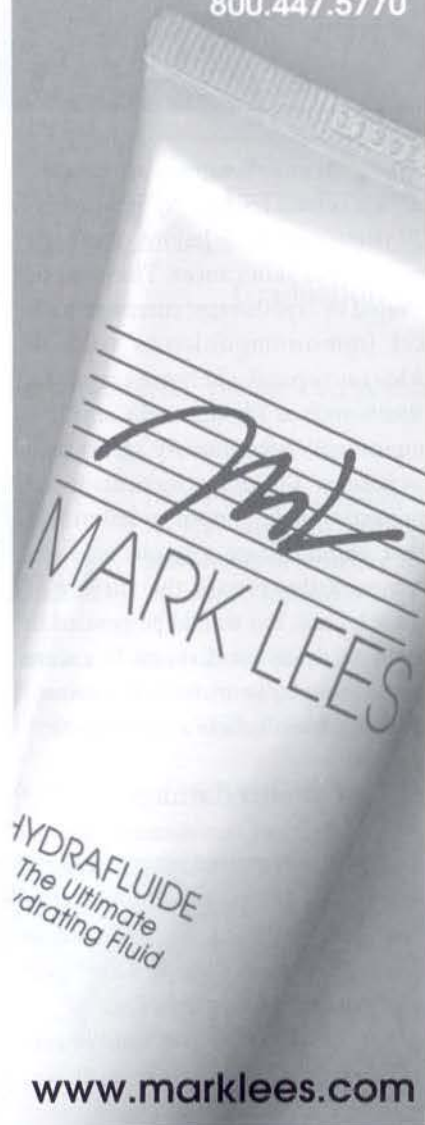
*continues*

non-clogging

**MARK LEES**  
Science...Made Beautiful

Join the thousands of skin care professionals who have discovered Dr. Mark Lees' time-tested methods & non-clogging products for acne-prone, dehydrated, sensitive, and aging skin.

Call today to place your opening order!  
800.447.5770



[www.marklees.com](http://www.marklees.com)

Reader Service No. 168

exposure can begin to show evidence of sun damage as early as their late 20s and early 30s. Early changes including blotchy pigmentation, fine lines and dull complexions can be treated with sun protection, prescription topical retinoids and superficial peeling. The addition of topical cosmeceuticals such as copper creams and creams containing niacinamide, green tea and growth factors can also be beneficial. Superficial peeling and pigmented lesion laser treatments can also be helpful for blotchy pigmentation. Early crow's-feet can be treated with Botox, as well. LED photomodulation can stimulate collagen production improving skin color and pores and diminishing fine lines. Ablative laser resurfacing is generally reserved for more advanced photoaging.

#### Micro-summer

**Q:** Should you have microdermabrasion in the summer? Won't it cause hyperpigmentation?

**A:** Superficial microdermabrasion can be performed in the summer if patients are careful with sun protection. Any peeling procedure can result in hyperpigmentation if patients do not avoid sun exposure following treatment. Patients interested in skin rejuvenation should be encouraged to comply with sun protection as part of their rejuvenation therapy.

#### What's the frequency?

**Q:** I heard that radiofrequency is painful and the results are not always predictable. Is this true?

**A:** Yes, radiofrequency treatments with Thermage are painful and most patients require sedation to tolerate treatments. The results are variable with many patients experiencing minimal to no change. Improvement, if any, is usually delayed for up to six months.

#### Itchy and scratchy bites

**Q:** What's the best way to treat a mosquito bite? How can you stop it from itching? My eight-year-

old daughter has torn up her legs from scratching so much. She has scabs that bleed. I don't want her to scar, but it's hard to convince an eight-year-old girl to have self-control when itching is so intense.

**A:** The best treatment for itching related to insect bites is a prescription topical steroid. Over-the-counter antipruritic agents that contain menthol and phenol can also be helpful but may sting if applied to open sore areas. Cool soaks can temporarily ease itching and the addition of an antihistamine may also be helpful. If scratching has resulted in open sores, you should seek consultation with a dermatologist.

#### Oops! Self-tanning mistakes

**Q:** What's the best way to remedy a self-tanner mistake? I have a client who has put too much self-tanner on her body and it's streaky. I thought performing a body scrub would help, but perhaps you have a better suggestion. She looks pretty funny; she didn't even wear gloves, so her hands are tanned, too.

**A:** Exfoliation with a body scrub will hasten removal of the self-tanner stain in the stratum corneum and is the best way to remedy an incorrect application. ■

*Debra Price, M.D., graduated from New York University School of Medicine and interned at New York University Medical Center. She is a diplomate of the American Board of Dermatology and an assistant professor at University of Miami's department of dermatology and cutaneous surgery. Author of several scientific papers,*



*Dr. Price is an award-winning dermatologist and past president of the Miami Dermatologic Society, in Florida. She has a private practice in Kendall, FL. To reach her, please call (305) 670-1111.*